Twinkle 東京女子医科大学学術リポジトリ
Tokyo Women's Medical University - Information & Knowledge Database
https://twinkle.repo.nii.ac.jp

Multiple Coronary Artery/Ventricular Microfistulas: A Late Complication of Fontan Surgery?

メタデータ	言語: English 出版者: 公開日: 2022-02-18 キーワード (Ja): キーワード (En): 作成者: YOSHIZAWA, Saeko , MORI, Hiroki , NIIDA, Motoko , UTO, Kenta , NISHIKAWA, Toshio , ODA, Hideaki メールアドレス: 所属:
URL	http://hdl.handle.net/10470/00033131

This work is licensed under a Creative Commons Attribution-NonCommercial-ShareAlike 3.0 International License.

Canadian Journal of Cardiology 37 (2021) 523.e5–523.e6 www.onlinecjc.ca

Images in Cardiology

Multiple Coronary Artery/Ventricular Microfistulas: A Late Complication of Fontan Surgery?

Saeko Yoshizawa, MD, PhD,[a] Hiroki Mori, MD,[b] Motoko Niida, MD, PhD,[a] Kenta Uto, MD,[a] Toshio Nishikawa, MD, PhD,[c] and Hideaki Oda, MD, PhD[a]

[a] *Department of Pathology, Tokyo Women's Medical University, Tokyo, Japan*

[b] *Department of Pediatric Cardiology, Tokyo Women's Medical University, Tokyo, Japan*

[c] *Department of Surgical Pathology, Tokyo Women's Medical University, Tokyo, Japan*

A 16-year-old girl with a history of Fontan surgery for single right ventricle, common atrioventricular valve, common atrium, and pulmonary stenosis at 4 years of age was admitted because of Fontan circulatory failure (FCF). Angiography performed at 9 years of age revealed left coronary artery tortuosity and coronary artery/ventricular microfistulas (CAMFs) with a hypoplastic right coronary artery and an ejection fraction of 53% (Fig. 1A; Video 1, view video online). During treatment of FCF, she suffered a brain hemorrhage caused by a dural arteriovenous fistula of the transverse–sigmoid sinus. Despite extensive treatment, she died of sepsis. An autopsy revealed multiple dilated blood vessels with unique undulating shapes surrounded by sparse fibrosis, both grossly and histologically, within the ventricular myocardium from the subendocardium to the midwall (Fig. 1B-E), with an opening into the ventricular chamber (Fig. 1F). Vessel diameter varied from several hundred micrometers to 1 millimeter (approximately the same size as small arteries or veins); however, smooth muscle cells and elastic fibers were sparse in the vessel walls (Supplemental Fig. S1, A-D). Immunohistochemically, the vessels were lined by $CD31^{+}$ endothelial cells, and were negative for D2-40 (Supplemental Fig. S1, E,F). These pathological features were consistent with those of residual sinusoids, which cause CAMFs.

The prognosis of children with congenital heart disease has dramatically improved in recent years owing to advances in medical and surgical treatments. At present, the management of late complications in patients surviving until adulthood is a major concern. Several cases of CAMFs in univentricular circulation, with or without history of Fontan surgery, have been reported; however, their frequency and pathogenesis remain unclear.[1,2] To the best of our knowledge, this is the first case of CAMF identified by both angiography and pathological examination. Sinusoidal connections may develop and cause CAMFs late after Fontan surgery, which can affect FCF.

Funding Sources

No funding sources were provided for this article.

Disclosures

The authors have no conflicts of interest to disclose.

References

1. Baffa JM, Chen SL, Guttenberg ME, Norwood WI, Weinberg PM. Coronary artery abnormalities in right ventricular histology in hypoplastic left heart. J Am Coll Cardiol 1992;20:350-8.

2. Finn D, Walsh K, Roberson D, McMahon CJ. Myocardial fistulisation and coronary arterial ectasia in children with univentricular circulation: an under-recognised problem. Pediatr Cardiol 2018;39:254-60.

Supplementary Material

To access the supplementary material accompanying this article, visit the online version of the *Canadian Journal of Cardiology* at www.onlinecjc.ca and at https://doi.org/10.1016/j.cjca.2020.09.004.

Received for publication July 29, 2020. Accepted September 9, 2020.

Corresponding author: Dr Saeko Yoshizawa, Tokyo Women's Medical University, Department of Pathology, 8-1 Kawada-cho, Shinjuku-ku, Tokyo 162-8666, Japan. Tel.: +81-3-3353-8111; fax: +81-3-5269-7473.

E-mail: yoshizawa.saeko@twmu.ac.jp

See page 523.e5 for disclosure information.

https://doi.org/10.1016/j.cjca.2020.09.004

0828-282X/© 2020 The Authors. Published by Elsevier Inc. on behalf of the Canadian Cardiovascular Society. This is an open access article under the CC BY-NC-ND license (http://creativecommons.org/licenses/by-nc-nd/4.0/).

Downloaded for Anonymous User (n/a) at Tokyo Women Medical University - Library from ClinicalKey.jp by Elsevier on February 16, 2022. For personal use only. No other uses without permission. Copyright ©2022. Elsevier Inc. All rights reserved.

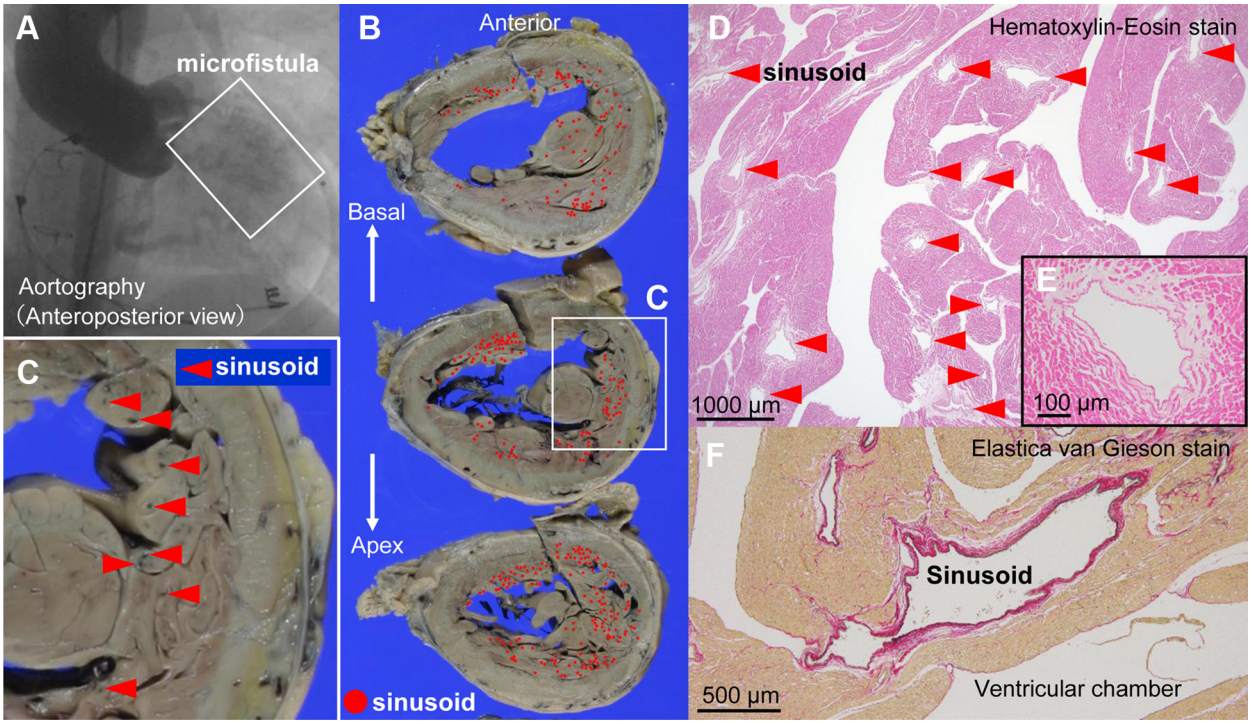

Figure 1. Aortography and pathology images. (**A**) Aortography showing coronary artery/ventricular microfistulas (CAMFs) (**white box**). (**B**) Mapping of CAMFs (**red circle**) in gross images of autopsied heart. (**C**) Enlarged Figure 1B, with **arrowheads** indicating CAMFs. (**D-F**) Histological images of CAMFs stained with hematoxylin-eosin (**D, E**) and Elastica van Gieson (**F**).

Downloaded for Anonymous User (n/a) at Tokyo Women Medical University - Library from ClinicalKey.jp by Elsevier on February 16, 2022. For personal use only. No other uses without permission. Copyright ©2022. Elsevier Inc. All rights reserved.