

## Submandibular Gland Hemangioma

メタデータ	言語: eng 出版者: 公開日: 2021-04-30 キーワード (Ja): キーワード (En): 作成者: SASAKI , Ryo , OKAMOTO, Toshihiro , KUDO, Satoshi, YAMAMOTO, Tomoko , ANDO, Tomohiro メールアドレス: 所属:
URL	<a href="http://hdl.handle.net/10470/00032765">http://hdl.handle.net/10470/00032765</a>

This work is licensed under a Creative Commons Attribution-NonCommercial-ShareAlike 3.0 International License.



# Submandibular Gland Hemangioma

Ryo Sasaki, DDS, PhD, FIBCSOMS\*  
 Toshihiro Okamoto, DDS, PhD\*  
 Satoshi Kudo, DDS\*  
 Tomoko Yamamoto, MD, PhD†  
 Tomohiro Ando, DDS, PhD\*

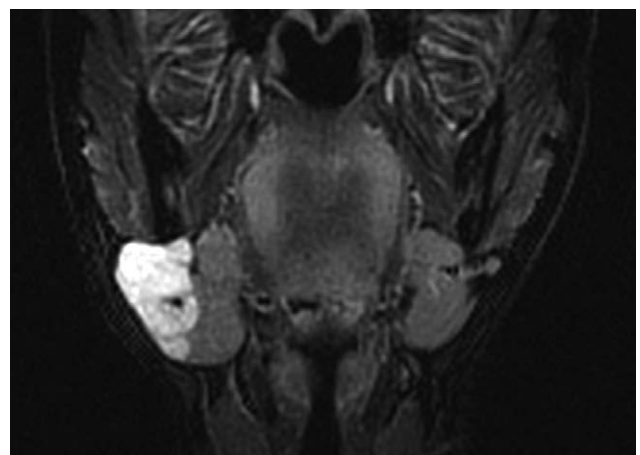
**Summary:** Hemangioma in the submandibular gland or submandibular space is rare. A 31-year-old woman was referred to our department. She became aware of painless swelling in the right submandibular gland at 9 months ago. The right submandibular gland showed swelling with no tenderness, and the palpation was softer than the normal submandibular gland. Magnetic resonance imaging short T1 inversion recovery (STIR) sequence showed a 38×29 mm well-circumscribed, lobulated mass with high signal intensity attached with the submandibular gland. Computed tomography showed phlebolith formation. A clinical diagnosis of suspected hemangioma in submandibular gland was made, and submandibular gland excision including mass was performed with submandibular approach without complications. No unusual bleeding during the surgery was observed. Pathological finding indicated that thick walled vessels containing smooth muscle were proliferated with dilatation. Some vascular lumen included phlebolith calcification. Although the boundary with the submandibular gland was mainly clear, some parts were irregularly occupied with a component of hemangioma. The final diagnosis was venous hemangioma in submandibular gland. No postoperative recurrence was recognized in 1-year follow-up. A search of PubMed revealed that only 18 cases associated with hemangioma in the submandibular gland in 12 English articles. Literature review indicated that (1) approximately 70% patients showed painful swelling and (2) x-ray or computed tomography may indicate the phlebolith calcification. It may make an erroneous diagnosis of sialolithiasis. Magnetic resonance imaging finding would be needed for the diagnosis. (*Plast Reconstr Surg Glob Open* 2019;7:e2304; doi: 10.1097/GOX.0000000000002304; Published online 5 July 2019.)

**H**emangioma in the submandibular gland or submandibular space is rare.<sup>1</sup> In this study, Hemangioma in the submandibular gland in 31-year-old female patient was reported. Moreover, literature review was performed in the submandibular gland hemangioma.

## CLINICAL REPORT

A 31-year-old woman was referred to our department. She became aware of painless swelling in the right submandibular gland at 9 months ago. The right submandibular gland showed swelling with no tenderness, and the palpation was softer than the normal submandibular

gland. She had no medical history and no medication. Magnetic resonance imaging (MRI) findings revealed that the mass showed an equal signal in T1-weighted sequence and a high-signal intensity in T2-weighted sequence. MRI STIR sequence showed a 38×29 mm well-circumscribed, lobulated mass with high-signal intensity attached with



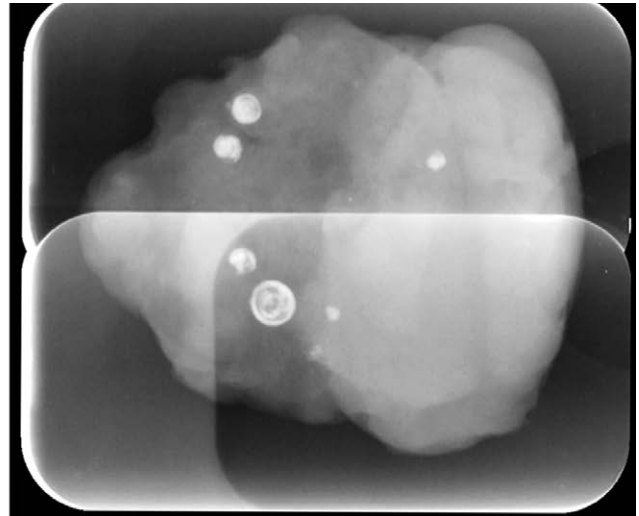
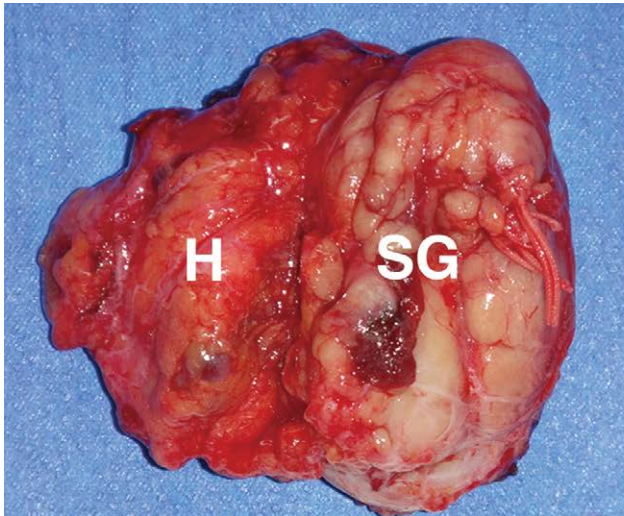
**Fig. 1.** MRI finding. MRI STIR sequence coronal image showed a 38×29 mm well-circumscribed, lobulated mass with high signal intensity attached with the submandibular gland.

From the \*Department of Oral and Maxillofacial Surgery, Tokyo Women's Medical University, School of Medicine, 8-1 Kawada-cho, Shinjuku-ku, Tokyo 162-8666, Japan; and †Department of Surgical Pathology, Tokyo Women's Medical University, School of Medicine, 8-1 Kawada-cho, Shinjuku-ku, Tokyo 162-8666, Japan. Received for publication April 5, 2019; accepted April 26, 2019.

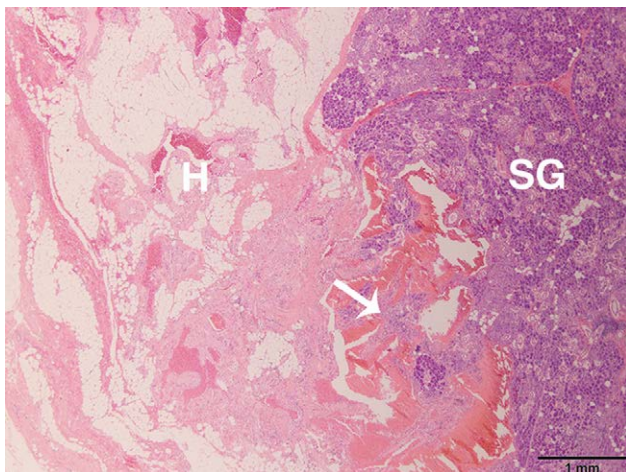
Copyright © 2019 The Authors. Published by Wolters Kluwer Health, Inc. on behalf of The American Society of Plastic Surgeons. This is an open-access article distributed under the terms of the Creative Commons Attribution-Non Commercial-No Derivatives License 4.0 (CCBY-NC-ND), where it is permissible to download and share the work provided it is properly cited. The work cannot be changed in any way or used commercially without permission from the journal.

DOI: 10.1097/GOX.0000000000002304

**Disclosure:** The authors have no financial interest to declare in relation to the content of this article.



**Fig. 2.** Photograph of the resected specimen and the X-ray image. A, The resected specimen. The mass (H) was well circumscribed and connected to the SG. B, x-ray image of the resected specimen. It showed phlebolith formation. The mass (left side) was well circumscribed and connected to the SG (right side). H, hemangioma; SG, submandibular gland.



**Fig. 3.** HE-stained specimen. HE finding indicated that proliferation of dilated vessels was observed. Although the boundary with the SG was mainly clear, some parts were irregularly occupied with a component of hemangioma (arrow shows). H, hemangioma; HE, hematoxylin and eosin; SG, submandibular gland.

the submandibular gland (Fig. 1). Computed tomography showed phlebolith formation. A clinical diagnosis of suspected hemangioma in submandibular gland was made and scheduled for surgical excision under general anesthesia. Submandibular gland excision including mass was performed with submandibular approach without complications. No unusual bleeding during the surgery was observed, and the total blood loss during the surgery equaled 133 mL. The resected specimen showed well-circumscribed and connected to the submandibular gland (Fig. 2A). X-ray image of the resected specimen showed phlebolith formation (Fig. 2B). Pathological finding indicated that thick-walled vessels containing smooth muscle were proliferated with dilatation. Some vascular lumen included phlebolith calcification. Although the boundary

with the submandibular gland was mainly clear, some parts were irregularly occupied with a component of hemangioma (Fig. 3). The final diagnosis was venous hemangioma in submandibular gland. No postoperative recurrence was recognized in 1-year follow-up.

## DISCUSSION

Hemangioma in the submandibular gland is rare. There is no hemangioma in submandibular gland in 779 cases of salivary gland tumors during 25 years in a single hospital, although there are 3 cases of hemangioma in parotid gland.<sup>1</sup> A search of PubMed revealed only 18 cases associated with hemangioma in the submandibular gland in 12 English articles.<sup>2-12</sup> Of these 18 cases, 11 cases (61%) occurred in female and 7 cases (39%) occurred in male. The mean age of the patients was  $37.6 \pm 4.0$  years old (range, 7-70 years). Pathological type of hemangioma in submandibular gland was cavernous (17 cases) and venous (1 case).<sup>2-12</sup> Venous hemangioma is rare in submandibular gland hemangioma,<sup>3</sup> although our case showed venous hemangioma. Although in this case the patient showed painless swelling of submandibular gland, 67% patients showed painful swelling of submandibular gland such as sialadenitis.<sup>2,3,6-12</sup> There is no report of massive bleeding in surgical excision.<sup>2-12</sup> Cho et al.<sup>6</sup> reported that the amount of bleeding was not severe, except in the case in which the feeding vessel was not ligated in their 4 cases. Aynali et al.<sup>4</sup> reported that there was an unusual bleeding during dissection from hemangiomatous areas. Kumar et al.<sup>7</sup> reported that preoperative embolization conferred no benefit in terms of reducing intraoperative blood loss (mean blood loss: 310 mL, with embolization,  $n = 2$ , versus 340 mL, without embolization,  $n = 2$ ). No recurrence has been reported.<sup>2-12</sup> In conclusion, hemangioma in submandibular gland is rare, literature review indicated that (1) approximately 70% patients showed painful swelling<sup>2,3,6-12</sup> and (2) x-ray or computed tomography may indicate the phlebolith calcification.<sup>4,6,7,10-12</sup> It may make an

erroneous diagnosis of sialolithiasis.<sup>4,10,12</sup> MRI would be required for the diagnosis.

**Dr. Ryo Sasaki**

Department of Oral and Maxillofacial Surgery  
Tokyo Women's Medical University, School of Medicine  
8-1 Kawada-cho, Shinjuku-ku  
Tokyo 162-8666  
Japan  
E-mail: sasaki.ryo@twmu.ac.jp

#### REFERENCES

1. Lukšić I, Virag M, Manojlović S, et al. Salivary gland tumours: 25 years of experience from a single institution in Croatia. *J Craniomaxillofac Surg.* 2012;40:e75–e81.
2. Azadarmaki R, Then MT, Walia R, et al. Cavernous hemangioma of the submandibular gland with parapharyngeal extension in an adult: case report. *Ear Nose Throat J.* 2016;95:E11–E13.
3. Wallace AN, Vyhmeister R, Kamran M, et al. Submandibular venous hemangioma: case report and review of the literature. *J Clin Ultrasound.* 2015;43:516–519.
4. Aynalı G, Ünal F, Yarıktaş M, et al. Submandibular hemangioma with multiple phleboliths mimicking sialolithiasis: the first pediatric case. *Kulak Burun Bogaz İhtis Derg.* 2014;24:168–171.
5. Ozturk M, Sari F, Erdogan S, et al. Submandibular cystic cavernous hemangioma: an unusual presentation. *J Craniofac Surg.* 2013;24:1856–1857.
6. Cho JH, Nam IC, Park JO, et al. Clinical and radiologic features of submandibular triangle hemangioma. *J Craniofac Surg.* 2012;23:1067–1070.
7. Kumar S, Gupta AK, Bakshi J. Submandibular gland hemangioma: clinicopathologic features and a review of the literature. *Ear Nose Throat J.* 2010;89:E14–E17.
8. Chuang CC, Lin HC, Huang CW. Submandibular cavernous hemangiomas with multiple phleboliths masquerading as sialolithiasis. *J Chin Med Assoc.* 2005;68:441–443.
9. El-Hakim IE, El-Khashab MM. Cavernous haemangioma of the submandibular salivary gland. *Int J Oral Maxillofac Surg.* 1999;28:58–59.
10. McMenamin M, Quinn A, Barry H, et al. Cavernous hemangioma in the submandibular gland masquerading as sialadenitis: case report. *Oral Surg Oral Med Oral Pathol Oral Radiol Endod.* 1997;84:146–148.
11. Bowerman JE, Rowe NL. Haemangiomas involving the submandibular salivary gland. *Br J Oral Surg.* 1970;7:196–201.
12. Hopkins R. Submandibular sialolithiasis with a case of a cavernous haemangioma presenting as a salivary calculus. *Br J Oral Surg.* 1969;6:215–221.