

Robot-Assisted Thoracoscopic Tumor Resection of Lymph Node Metastasis of an Unknown Primary Site: A Case Report

メタデータ	言語: eng 出版者: 公開日: 2021-02-02 キーワード (Ja): キーワード (En): 作成者: ISAKA, Tamami, MITSUBOSHI, Shota, SHIDEI, Hiroaki, AOSHIMA, Hiroe, MATSUMOTO, Takako, SAWADA, Tatsuo, NAGASHIMA, Yoji, KANZAKI, Masato メールアドレス: 所属:
URL	http://hdl.handle.net/10470/00032754

Robot-Assisted Thoracoscopic Tumor Resection of Lymph Node Metastasis of an Unknown Primary Site: A Case Report

Tamami Isaka,¹ Shota Mitsuboshi,¹ Hiroaki Shidei,¹ Hiroe Aoshima,¹
Takako Matsumoto,¹ Tatsuo Sawada,² Yoji Nagashima,³ and Masato Kanzaki¹

¹Department of Thoracic Surgery, Tokyo Women's Medical University, Tokyo, Japan

²Division of Pathological Neuroscience, Department of Pathology, Tokyo Women's Medical University School of Medicine, Tokyo, Japan

³Department of Surgical Pathology, Tokyo Women's Medical University, Tokyo, Japan

(Accepted August 12, 2020)

(Advance Publication by J-STAGE September 25, 2020)

Cancer of an unknown primary site (CUP) accounts for approximately 3% of all cancer cases. Among these cases, mediastinal lymph node cancer is comparatively rare, and there are no established treatment methods or approaches. Excision of CUP is feasible with the best methods. We herein report a case of mediastinal lymph node CUP resection by robot-assisted thoracoscopic surgery (RATS). The patient was a 60-year-old man. A chest computed tomography (CT) scan identified swelling in the mediastinal lymph node (right tracheobronchial lymph node; #4R) with another organ suspected as the site of the primary lesion, but it was not detected through positron emission tomography (PET). The patient was diagnosed with CUP with lymph node metastasis and mediastinal lymph node dissection was performed via RATS. Histopathological examination revealed desmoplasia in the lymph nodes. Immunohistochemically, the tumor was positive for CK7, TTF1, and napsin A, but negative for CK20, CK5/6, CDX2, p40, and AFP, indicating lung-derived adenocarcinoma. In the narrow space such as the mediastinum, RATS is a useful procedure for resectable mediastinal tumors.

Key Words: robot-assisted thoracoscopic surgery (RATS), cancer of unknown primary site (CUP)

Introduction

Cancer of an unknown primary site (CUP) accounts for approximately 3% of all the clinical cancer cases, and it is frequently linked with mortality.^{1,2} Among these cases, mediastinal lymph nodal involvement is comparatively rare, and there are no established therapeutic strategies.³ To determine the primary site and select an appropriate therapeutic regimen, biopsy and/or excision of the CUP

is required. Furthermore, the resected tissue sample can be used for comprehensive cancer genome analysis which will also assist with selecting an appropriate therapeutic option for CUP.^{3,4}

We herein report a case of CUP metastasizing to the mediastinal lymph node. The lesion was successfully resected by robot-assisted thoracoscopic surgery (RATS). Histopathologically, the lung was indicated as the primary site.

Corresponding Author: Masato Kanzaki, Department of Thoracic Surgery, Tokyo Women's Medical University, 8-1 Kawada-cho, Shinjuku-ku, Tokyo 162-8666, Japan. kanzaki.masato@twmu.ac.jp

doi: 10.24488/twmuj.2020006

Copyright © 2020 Society of Tokyo Women's Medical University. This is an open access article distributed under the terms of Creative Commons Attribution License (CC BY), which permits unrestricted use, distribution, and reproduction in any medium, provided the original source is properly credited.

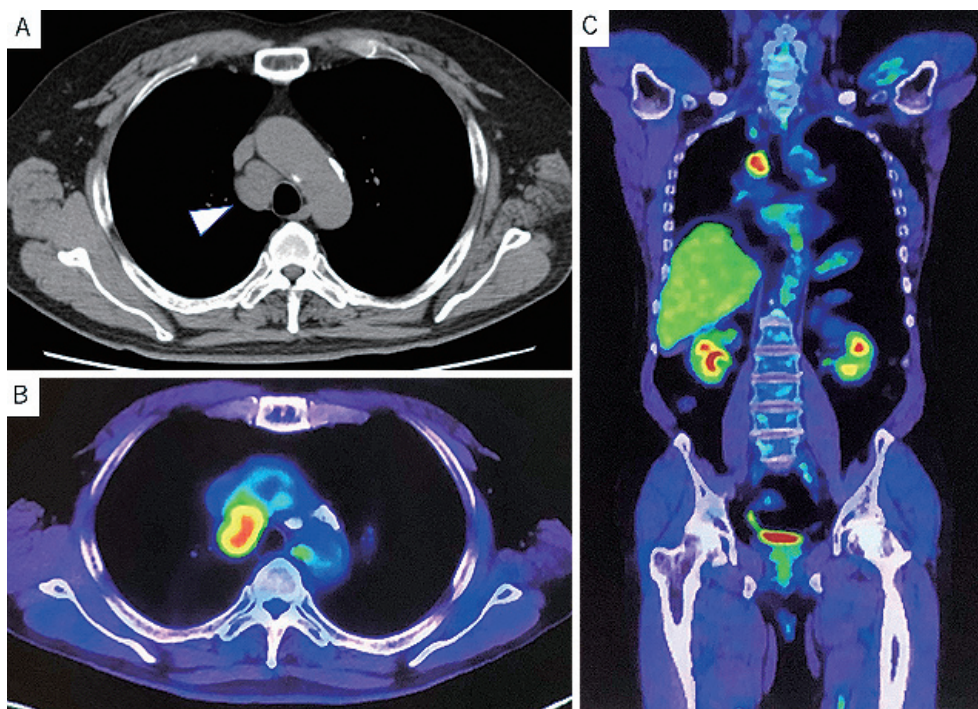


Figure 1 Preoperative imaging findings.

(A) Chest computed tomography scan showing a solitary mediastinal mass with 37 mm in maximum diameter without invasion surrounding tissues.

(B) 18F-fluorodeoxyglucose positron emission tomography (FDG-PET) of the patient showing an abnormal uptake of FDG with a maximum standardized uptake value of 5.92 in the tumor.

(C) Coronal section of the FDG-PET showing no abnormal FDG accumulation other than the tumor.

Case Presentation

A 60-year-old man presented with a mediastinal tumor by chest computed tomography (CT) during medical checkup and was referred to our hospital. His physical findings were normal. He had been smoking 30 cigarettes per day for 37 years, had a comorbidity of hypertension, but had no past history of malignant tumors.

Although blood tests found elevated Sialyl Lewis X (SLX) levels of 61 U/mL, both carcinoembryonic antigen (CEA) and cytokeratin subunit 19 fragment (CYFRA) levels were normal. No other abnormalities were identified in the blood sample.

Chest CT revealed an isolated mediastinal mass measuring 37 mm in the maximum diameter without invasion to the adjacent tissues. No abnormal shadows were identified in the lung fields (**Figure 1 A**). 18 F-fluorodeoxyglucose (FDG) accumulation was identified in the tumor using FDG positron emission tomography (PET), and the maximum standardized uptake value was 5.92. No abnormal FDG accumulation was found in

other organs (**Figure 1B and C**).

Endobronchial ultrasound transbronchial needle aspiration (EBUS-TBNA) was performed and he was diagnosed with adenocarcinoma. Since no primary site organ could be identified, the diagnosis was mediastinal lymph node CUP, and robot-assisted thoracoscopic surgery (RATS) was performed.

The patient was intubated with a double-lumen endotracheal tube for one-lung ventilation under general anesthesia, and placed in a left lateral decubitus position. RATS excision of the mediastinal tumor was performed with four port incisions and a 4-cm utility thoracotomy as an assistant port. The da Vinci Surgical System (Model Xi; Intuitive Surgical, Inc, Sunnyvale, CA, USA) was used. RATS began with a total of four 8-mm ports inserted in the 7th intercostal space (ICS) at the anterior side as the 1st arm, in the 8th ICS mid-axillary line as the 2nd arm, in the 8th posterior axillary line as the 3rd arm, and in the 8th posterior side as the 4th arm, plus an assistant port in the 4th ICS (**Figure 2**). A robotic arm was mounted to the port in the 8th ICS, with Cadere grasping

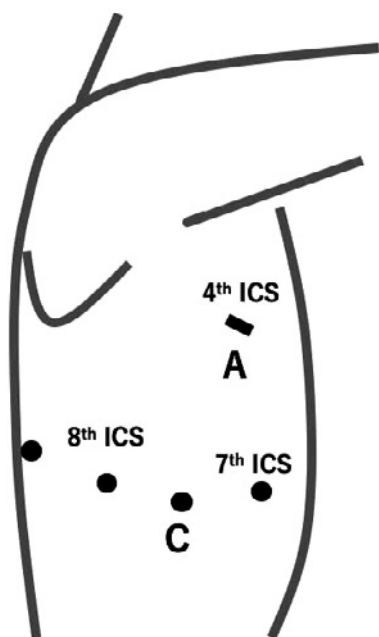


Figure 2 Schematic illustration of four port incisions and a 4-cm utility thoracotomy as an assistant port.

A total of four 8-mm ports (circle) were inserted in anterior to 7th intercostal space (ICS), 8th ICS mid-axillary line, posterior axillary line, and posterior. An assistant port (line) was made at 4th ICS.

ICS, intercostal space; A, assistant port; C, camera.

forceps on the 1st arm, bipolar fenestrated grasping forceps on the 2nd arm, and monopolar spatula on the 4th arm. The camera scope was inserted into the 8th ICS mid-axillary line port and was used for 30° oblique viewing. No adhesions were found within the right thoracic cavity, and there were no abnormalities in the lungs. The tumor was located in the right lower paratracheal lymph nodes (4R) on the cranial side of the azygos vein (**Figure 3A**). After the pleura was incised in a cephalad direction, the azygos vein and tumor were exposed. For amputating the azygos vein, an EndoWrist stapler was used through the 4th arm port (**Figure 3B**). The mediastinal fat pad including the tumor was dissected off the superior vena cava and anterolateral tracheal surface (**Figure 3C and D**). The resected mediastinal tumor was placed in a bag and removed through the assistant port, followed by the insertion of a 21-Fr silicon tube through the camera port. The tumor was measured 4.5 × 3.5 × 2.5 cm (**Figure 4**). Macroscopic finding of the tumor was yellow-whitish surface.

Histopathologically, the resected lymph node was occupied by tumor cells with a solid architecture. The tu-

mor cells were large in size and polygonal in shape. Their nuclei were large with a vesicular appearance and prominent nucleoli. The cytoplasm was pale. Based on these findings, a germ cell tumor, lymphoma, and malignant melanoma were considered as differential diagnostic candidates along with metastatic carcinoma (**Figure 5A**). Immunohistologically, the tumor cells were positive for cytokeratin (CK) 7, thyroid transcription factor-1 (TTF-1), and napsin A, while negative for CK20, CK5/6, caudal related homeobox gene type 2 (CDX2, p40, and α -fetoprotein (AFP) (**Figure 5B-F**). Based on these findings, he was diagnosed with metastatic adenocarcinoma, the primary site of which was considered to be the lung. Genetic tests failed to reveal any mutation of *epidermal growth factor receptor (EGFR)* and translocation involving *anaplastic lymphoma kinase (ALK)* and *c-ros oncogene 1 (ROS1)*. The postoperative course was uneventful. The chest tube was removed on the 4th day, and he was discharged on the 7th day after surgery. Postoperative adjuvant chemotherapy was received according to the treatment for lung cancer. The patient showed no evidence of recurrence at the 15-month follow-up.

Discussion

CUP refers to metastasized cancer for which the primary site cannot be identified. This condition is usually seen in the liver, lungs, and bones. In this case, the mediastinal lymph nodes showed isolated metastasis, although it accounts for just 1.5% of all CUP involvements.⁵ Most common histological types of CUP are adenocarcinoma, followed by undifferentiated carcinoma and squamous cell carcinoma.^{1,6}

Sampling procedures of mediastinal lymph node CUP include bronchoscopy, thoracoscopy, mediastinoscopy, and surgical procedures. Differentiating diagnosis between CUP, other tumors originating in the mediastinum, and malignant lymphoma is essential. In addition, since future developments in cancer genome analysis are helpful for both the diagnosis and treatment selection of CUP,² sampling of sufficient tumor tissue is important. As a result, biopsy and/or excision of mediastinal tumors are the best methods.

The robotic surgical system provides a 3-dimensional view and dedicated robotic instruments that have com-

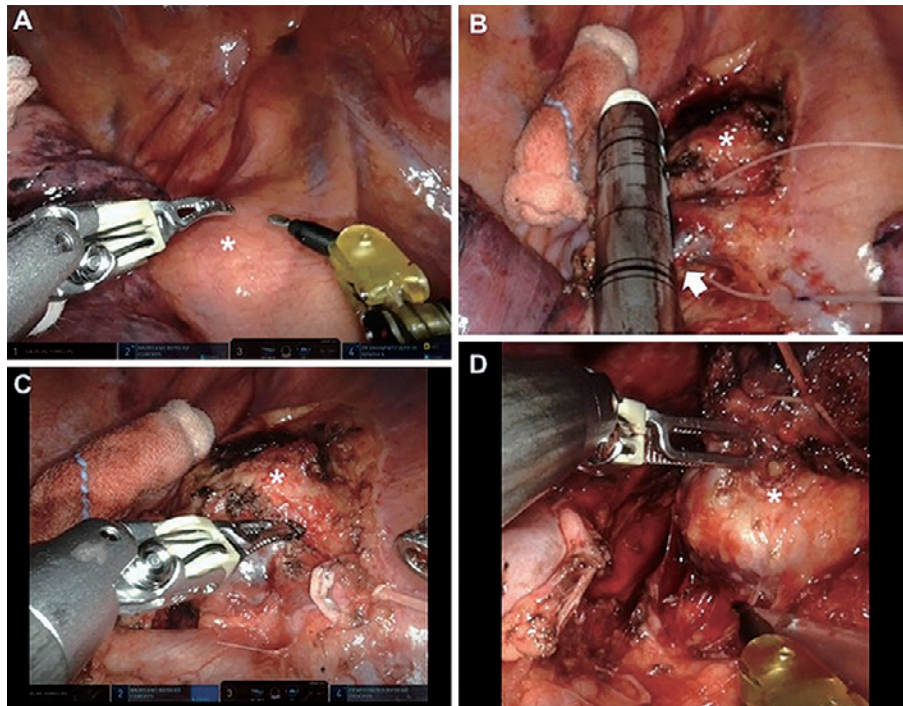


Figure 3 The intraoperative screenshot of the robot-assisted thoracoscopic surgery (RATS). (A) The tumor (*) was located in right lower paratracheal lymph nodes (4R) on the cranial side of the azygos vein. (B) After the pleura was incised in a cephalad direction, azygos vein (white arrow) and the tumor were exposed. The azygos vein was amputated by robotic stapler. (C) The mediastinal fat pad including the tumor was dissected off superior vena cava. (D) The mediastinal fat pad including the tumor was dissected off the anterolateral tracheal surface and removed.

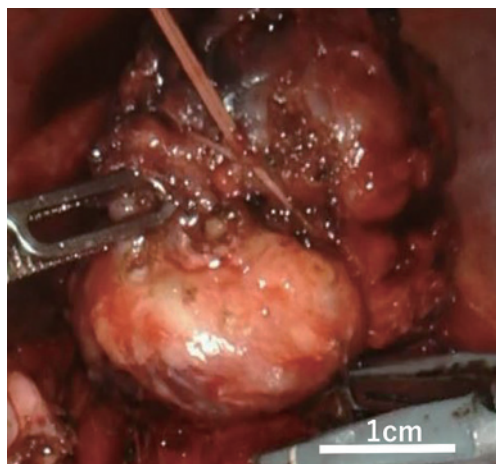


Figure 4 The intraoperative view of the tumor. The intraoperative view of the tumor was extracted from digital video data taken during the operation and was provided on a personal computer after operation.

portable motions with 7 degrees of freedom in the thoracic cavity. Although the mediastinum with lymph node is tightly packed with intertwined organs, the robotic surgical system allowed for a smooth and natural manipula-

tion when performing surgical dissection. Especially, compared to the traditional video-assisted thoracic surgery (VATS) approach, robot-assisted surgery has been reported to be more effective for mediastinal lymph node dissection.⁷⁻⁹

Pathologically, seminoma, lymphoma, and malignant melanoma were considered as differential diagnostic candidates along with metastatic carcinoma. To determine the histological type and tumor origin, immunostaining was performed. Combined immunostainings for CK7 and CK20 are frequently employed to determine the primary site, especially of adenocarcinoma. TTF-1, SPA, and napsin A are characteristically positive for lung cancer, especially adenocarcinoma.^{10,11} In this case, the primary lesion site was in the lungs because the tumor was positive for TTF-1, CK7, and napsin A but negative for CK20.

Although most CUP are considered to signify advanced stage cancers, adjuvant chemotherapy following surgical resection is necessary for CUP. For mediastinal

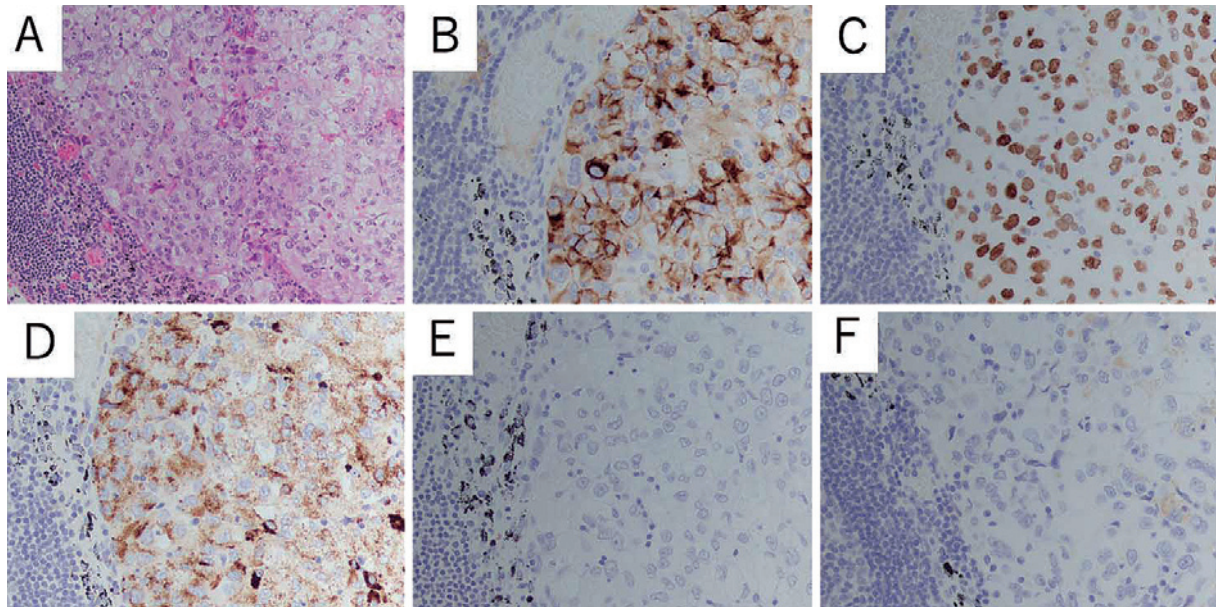


Figure 5 Microscopic findings of the resected specimen.

(A) Hematoxylin and eosin staining showing desmoplasia in the lymph nodes.

(B-F) Immunohistochemical examination revealing positive stain in (B) cytokeratin (CK) 7, (C) Thyroid transcription factor-1 (TTF-1), and (D) napsin A, and negative stain in (E) α -fetoprotein (AFP) and (F) CK20.

lymph node CUP, there are various postoperative care regimens. A variety of surgical treatments, such as pulmonary lobectomy and lymph node dissection are used. Observation and other treatments, including adjuvant chemotherapy, radiotherapy, or a combination of both chemotherapy and radiotherapy, are performed after surgical resection.^{3,12,13} The 5-year survival rate for CUP has been reported to range from 2-6%, but there are also reports that isolated mediastinal lymph node CUP has a comparatively better prognosis.¹³ In some reports, careful postsurgical investigation is required for mass shadows that appear in the lungs after the excision of mediastinal lymph node CUP.^{4,14,15}

Conclusion

RATS tumor resection was performed for mediastinal lymph node CUP. In narrow spaces, such as the mediastinum, RATS is a useful procedure for resectable CUP with mediastinal metastasis for the diagnosis and establishment of a therapeutic strategy.

Conflicts of Interest: The authors confirm no conflicts of interest.

References

1. Briasoulis E, Pavlidis N: Cancer of unknown primary origin. *Oncologist* 2 (3): 142–152, 1997
2. Vajdic CM, Perez-Concha O, Rhee JJ et al: Health-related predictors of cancer registry-notified cancer of unknown primary site (CUP). *Cancer Epidemiol* 61: 1–7, 2019
3. Nakano T, Watanabe H, Takeichi H et al: A case of mediastinal lymph node carcinoma of unknown primary site. *Tokai J Exp Clin Med* 43 (4): 148–152, 2018
4. Kawasaki H, Arakaki K, Taira N et al: Lung cancer detected 5 years after resection of cancer of unknown primary in a mediastinal lymph node: A case report and review of relevant cases from the literature). *Ann Thorac Cardiovasc Surg* 22 (2): 116–121, 2016
5. Holmes FF, Fouts TL: Metastatic cancer of unknown primary site. *Cancer* 26 (4): 816–820, 1970
6. Agca M, Kosif A: Metastatic squamous cell cancer with unknown primary origin in the mediastinal lymph node. *Niger J Clin Pract* 21 (10): 1384–1386, 2018
7. Kanzaki M: Current status of robot-assisted thoracoscopic surgery for lung cancer. *Surg Today* 49: 795–802, 2019
8. Nasir BS, Bryant AS, Minnich DJ et al: Performing robotic lobectomy and segmentectomy: cost, profitability, and outcomes. *Ann Thorac Surg* 98 (1): 203–208, 2014
9. Novellis P, Bottoni E, Voulaz E et al: Robotic surgery, video-assisted thoracic surgery, and open surgery for early stage lung cancer: comparison of costs and outcomes at a single institute. *J Thorac Dis* 10 (2): 790–798, 2018

10. Hirano T, Auer G, Maeda M et al: Human tissue distribution of TA02, which is homologous with a new type of aspartic proteinase, napsin A. *Jpn J Cancer Res* 91 (10): 1015–1021, 2000
 11. Chhieng DC, Cangiarella JF, Zakowski MF et al: Use of thyroid transcription factor 1, PE-10, and cytokeratins 7 and 20 in discriminating between primary lung carcinomas and metastatic lesions in fine-needle aspiration biopsy specimens. *Cancer* 93 (5): 330–336, 2001
 12. Morio A, Miyamoto H, Izumi H et al: A case report of adenocarcinoma of unknown origin metastatic to the mediastinal lymph nodes with a review of 21 cases reported in Japan. *Jpn J Lung Cancer* 41: 73–78, 2001 (in Japanese)
 13. Riquet M, Badoual C, Le Pimpec BF et al: Metastatic thoracic lymph node carcinoma with unknown primary site. *Ann Thorac Surg* 75 (1): 244–249, 2003
 14. Higuchi T, Nagata A, Hamada T et al: A case of primary lung cancer developing 9 years after surgery for metastatic mediastinal lymph node carcinoma. *J Jpn Assoc Chest Surg* 29: 220–225, 2015
 15. Hayashi K: A case report of a long-surviving patient with mediastinal lymph node carcinoma from an unknown primary site, with a review of 31 cases reported in Japan. *J Jpn Assoc Chest Surg* 21 (4): 624–629, 2007
-