

## Craniofacial fellowship at the Chang Gung memorial hospital: review of an 8-month fellowship experience

メタデータ	言語: eng 出版者: 公開日: 2019-04-10 キーワード (Ja): キーワード (En): 作成者: SASAKI, Ryo メールアドレス: 所属:
URL	<a href="http://hdl.handle.net/10470/00032163">http://hdl.handle.net/10470/00032163</a>

## Craniofacial Fellowship at the Chang Gung Memorial Hospital: Review of an 8-month Fellowship Experience

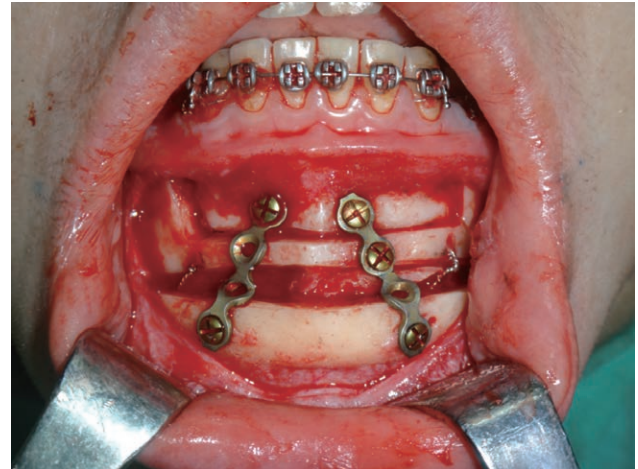
Ryo Sasaki, DDS, PhD

Sir:

Chang Gung Memorial Hospital (CGMH) in Taiwan was established in 1976. CGMH has 3,707 beds in the main branch at Linkou near Taipei. Linkou branch had 3,528,000 outpatients 1,067,000 hospitalized patients, and 91,000 surgical cases in 2014. CGMH has 7 branches in Taiwan and 2 branches in China. A craniofacial center was opened at Linkou in 1978 by Professor Noordhoff from the United States, expanded by Professor Y. R. Chen since 1997, and moved to Taoyuan branch newly completed in 2003 with 691 beds. The center consists of plastic surgeons and orthodontists, and approximately 600 orthognathic surgeries (OGSs) have been performed in 1 year that include surgery-first OGS,<sup>1</sup> maxilomandibular advancement for obstructive sleep apnea (OSA),<sup>2</sup> and computer-assisted surgery<sup>3</sup> as the characterized feature.

In this article, to share the author's experience with surgeons wanting to learn OGS, the author reviewed the craniofacial fellowship in CGMH for approximately 8 months from August 2014 to April 2015. This review was written by referring to a personal notebook, which recorded details of all attended surgical cases, including diagnosis and surgical technique.

The author observed 26 surgeries and assisted 82 surgeries and published 2 technical notes regarding his fellowship experience.<sup>4,5</sup> However, 3 manuscripts including a technical note, a case report, and an e-book chapter were still unpublished at 20 months after the end of the fellowship. Surgery was performed on every Monday, Tuesday, and Thursday. On every Monday morning, 2 scientific meetings were held, a meeting with Professor Y. R. Chen and international fellows and a research meeting with researchers. Moreover, on every Tuesday morning, another scientific meeting with residents was held. Craniofacial fellows had to present topics regarding OGS on Monday morning meeting, and every long-term craniofacial fellow had to present a review of fellowship at CGMH at the end of the fellowship on Tuesday morning meeting. At the Monday



**Fig. 1.** A surgical picture of the case assisted by the author. Le Fort I osteotomy, BSSO, anterior segmental maxillary osteotomy (Wassmund procedure), anterior segmental mandibular osteotomy (Köle procedure), and genioplasty with bone grafting were performed by Professor Y. R. Chen in bimaxillary protrusion.

**Table 1. Details of Diagnosis and Surgical Procedure in the Assisted Surgery (n = 82)**

	No. Cases (%)
<b>Diagnosis</b>	
Mandibular protrusion	39 (47.6)
Facial asymmetry	17 (20.7)
Mandibular retrusion	8 (9.8)
Bimaxillary protrusion	5 (6.1)
OSA	6 (7.3)
Others	7 (8.5)
<b>Procedures</b>	
Le Fort I and BSSO	28 (34.1)
Le Fort I, BSSO, and genioplasty	20 (24.4)
Le Fort I, Wassmund, and BSSO	3 (3.7)
Le Fort I, Wassmund, BSSO, and genioplasty	2 (2.4)
Le Fort I (3 pieces), BSSO, and genioplasty	3 (3.7)
Le Fort I (3 pieces) and BSSO	2 (2.4)
Le Fort I (3 pieces, subapical) and BSSO	1 (1.2)
Le Fort I, BSSO, genioplasty, and shaving	2 (2.4)
Le Fort I, Wassmund, Köle, and BSSO	1 (1.2)
Le Fort I, Wassmund, Köle, BSSO, and genioplasty	1 (1.2)
Le Fort I, Köle, BSSO, and genioplasty	1 (1.2)
Le Fort I, BSSO, and gonial angle reduction	1 (1.2)
Le Fort I, BSSO, genioplasty, and gonial angle reduction	1 (1.2)
Le Fort I, BSSO, genioplasty, and fat grafting	1 (1.2)
Wassmund, Köle, and BSSO	1 (1.2)
Genioplasty	1 (1.2)
Alloplastic genioplasty	1 (1.2)
Genioplasty and shaving	1 (1.2)
Mandibular contouring	1 (1.2)
BSSO, mandibular distal segment osteotomy, and bone grafting	1 (1.2)
SMMRA and genioplasty	2 (2.4)
Maxillomandibular advancement	1 (1.2)
Le Fort I, BSSO, genioplasty, and turbinoplasty	1 (1.2)
Others	5 (6.1)

Köle, anterior segmental mandibular osteotomy; Le Fort I, Le Fort I osteotomy; SMMRA, segmental maxillomandibular rotational advancement<sup>2</sup>; Wassmund, anterior segmental maxillary osteotomy.

From the Department of Oral and Maxillofacial Surgery, Tokyo Women's Medical University, School of Medicine, Tokyo, Japan.

Received for publication January 12, 2017; accepted January 20, 2017.

Copyright © 2017 The Authors. Published by Wolters Kluwer Health, Inc. on behalf of The American Society of Plastic Surgeons.

This is an open-access article distributed under the terms of the Creative Commons Attribution-Non Commercial-No Derivatives License 4.0 (CCBY-NC-ND), where it is permissible to download and share the work provided it is properly cited. The work cannot be changed in any way or used commercially without permission from the journal.

Plast Reconstr Surg Glob Open 2017;5:e1268; doi:10.1097/GOX.0000000000001268; Published online 28 March 2017.

meeting, the author presented 3 topics, which were (1) a review of genioplasty, (2) his previous scientific research, and (3) a review and a surgical technique of third molar removal during bilateral sagittal split ramus osteotomy (BSSO). On every Wednesday and Friday, by attending Professor Y. R. Chen's clinic or Professor Lin's clinic for OSA, the author was able to understand the details of examinations because medical charts were written in English. Craniofacial fellows have an opportunity to learn surgical planning from orthodontists and can attend with other teams including microsurgery or trauma teams. The surgery cases assisted by the author were mainly mandibular protrusion with maxillary hypoplasia (50%), followed by facial asymmetry (20%). And then, mainly bimaxillary surgery with or without genioplasty (60%) was performed, whereas 25% of the cases were complex combination osteotomies including bimaxillary surgery with segmental osteotomy (Fig. 1) or gonial angle reduction, and 3-piece Le Fort I osteotomy with BSSO (Table 1). In conclusion, the author was able to learn facial examination and surgical planning, surgical technique, and surgical approaches for OSA from specialists during the fellowship period. The most important achievement was the fact that the author could have mentoring for OGS.

**Ryo Sasaki, DDS, PhD**

Department of Oral and Maxillofacial Surgery  
Tokyo Women's Medical University  
School of Medicine  
8-1 Kawada-cho, Shinjuku-ku  
Tokyo 162-8666, Japan  
E-mail: sasaki@oms.twmu.ac.jp

#### ACKNOWLEDGMENTS

The author thanks Professor Y. R. Chen, Professor C. H. Lin, Dr. Y. A. Chen, Dr. C. F. Yao, Dr. D. Ho, Itziar, and Alberto for giving the author a great experience and Prof. T. Ando for giving the author a great opportunity for studying OGS in CGMH. The author also thanks Dr. K. Yamaguchi for giving the author information regarding CGMH.

#### DISCLOSURE

The author has no financial interest in any of the products or devices mentioned in this article. The Article Processing Charge was paid for by the Department of Oral and Maxillofacial Surgery, Tokyo Women's Medical University, School of Medicine, Tokyo, Japan.

#### REFERENCES

1. Liou EJ, Chen PH, Wang YC, et al. Surgery-first accelerated orthognathic surgery: orthodontic guidelines and setup for model surgery. *J Oral Maxillofac Surg*. 2011;69:771-780.
2. Lin CH, Liao YF, Chen NH, et al. Three-dimensional computed tomography in obstructive sleep apneics treated by maxillomandibular advancement. *Laryngoscope*. 2011;121:1336-1347.
3. Lonic D, Pai BC, Yamaguchi K, et al. Computer-assisted orthognathic surgery for patients with cleft lip/palate: from traditional planning to three-dimensional surgical simulation. *PLoS One*. 2016;11:e0152014.
4. Sasaki R, Cheung YC, Chan EC, et al. Iohexol oral rinse to differentiate the palatoglossal surfaces in computed tomography of patients with obstructive sleep apnoea. *Br J Oral Maxillofac Surg*. 2017;55:207-208.
5. Sasaki R, Yao CF, Chen YA, et al. Concomitant third molar removal during sagittal split osteotomy of the mandible. *J Craniofac Surg*. 2016;27:e34-e36.