Twinkle 東京女子医科大学学術リポジトリ
Tokyo Women's Medical University - Information & Knowledge Database
https://twinkle.repo.nii.ac.jp

Improvement in diagnostic performance of breast cancer: comparison between conventional digital mammography alone and conventional mammography plus digital breast tomosynthesis

メタデータ	言語: English 出版者: 公開日: 2019-04-13 キーワード (Ja): キーワード (En): 作成者: OHASHI, Ryoko, NAGAO, Michinobu, NAKAMURA, Izumi, OKAMOTO, Takahiro, SAKAI, Shuji メールアドレス: 所属:
URL	https://doi.org/10.20780/00031915

© The Japanese Breast Cancer Society 2018

Improvement in diagnostic performance of breast cancer: comparison between conventional digital mammography alone and conventional mammography plus digital breast tomosynthesis

[1]Ryoko Ohashi MD, [1]Michinobu Nagao MD, PhD, [1]Izumi Nakamura MD, [2]Takahiro Okamoto MD, PhD, and [1]Shuji Sakai MD, PhD.

1. Departments of Diagnostic Imaging and Nuclear Medicine, Tokyo Women's Medical University, Tokyo, Japan

2. Department of Breast and Endocrine Surgery, Tokyo Women's Medical University, Tokyo, Japan

Corresponding author: Dr. Ryoko Ohashi

Departments of Diagnostic Imaging and Nuclear Medicine, Tokyo Women's Medical University, 8- 1 Kawada-cho, Shinjuku-ku, Tokyo 162-8666, Japan.

Tel: +81-3-3353-8111

Fax: +81-3-5269-7531

E mail: ohashi.ryoko@twmu.ac.jp

Abstract

Background: The aim of this study was to determine if the diagnostic performance of breast lesion examinations could be improved by using both digital breast tomosynthesis (DBT) and conventional digital mammography (CDM).

Methods: Our institutional review board approved the protocol, and patients were provided the opportunity to opt out of the study. A total of 628 patients aged 22 to 91 years with abnormal screening results or clinical symptoms were consecutively enrolled between June 2015 and March 2016. All patients underwent DBT and CDM, and 1164 breasts were retrospectively analyzed by three radiologists who interpreted the results based on the Breast Imaging Reporting and Data System. Categories 4 and 5 were considered positive, and pathological results were the gold standard. The diagnostic performance of CDM and CDM plus DBT was compared using the mean areas under the receiver operating characteristic (ROC) curves.

Results: A total of 100 breast cancer cases were identified. The areas under the ROC curves were 0.9160 (95% confidence interval, 0.8779–0.9541) for CDM alone and 0.9376 (95% confidence interval, 0.9019–0.9733) for CDM plus DBT. The cut-off values for both CDM alone and CDM plus DBT measurements were 4, with sensitivities of 61.0% (61/100) and 83.0% (83/100), respectively, and specificities of 99.1% (1054/1064) and 98.9% (1052/1064), respectively. CDM yielded 39 false-negative diagnoses, while CDM plus DBT identified breast cancer in 22 of those cases (56.4%).

Conclusion: The combination of DBT and CDM for the diagnosis of breast cancer in women with abnormal examination findings or clinical symptoms proved effective and should be used to improve the diagnostic performance of breast cancer examinations.

Keywords: Breast cancer, conventional digital mammography, digital breast tomosynthesis, false negative, screening

Abbreviations: BI-RADS: Breast Imaging Reporting and Database System; CDM: conventional digital mammography; DBT: digital breast tomosynthesis; ROC: receiver operating characteristic.

Introduction

Conventional digital mammography (CDM) is widely used to screen for breast cancer and examine breast lesions [1-7]. However, CDM is limited by its inability to accurately distinguish suspicious lesions from adjacent overlapping tissue. Specifically, diagnosis becomes more challenging in instances of dense or heterogeneously dense breasts in terms of sensitivity and specificity [8, 9]. In Asian countries, including Japan, women's breasts are relatively small and highly dense [10, 11].

Digital breast tomosynthesis (DBT) is a three-dimensional imaging technique developed to overcome some of the limitations of CDM. During DBT, an X-ray tube moves through a limited arc angle and rebuilds the tissue in a series of thin slices to minimize the influences of breast tissue overlapping and structural noise [12]. Several studies have shown that DBT is a promising tool for breast cancer screening, as it is associated with decreased screening recall rates, increased cancer detection rates, and positive predictive values [13, 14].

While DBT has been extensively investigated, most previous studies have evaluated its use in screening programs [15, 16], while only a few have investigated its role in examining actual breast lesions. If DBT can resolve diagnostic difficulties of CDM caused by breast tissue overlapping structures and structural noise, then DBT would be useful for both screening and examinations. Therefore, the aim of this study was to determine if the diagnostic performance of breast lesion examinations could be improved by jointly using DBT and CDM for breast lesion examinations.

Materials and Methods

Study population

The study protocol was approved by our institutional review board, and the opt-out model (via website) was used. Patients were consecutively recruited between June 2015 and March 2016. Patients who had not undergone previous mammography at our hospital were enrolled in this study. Data were interpreted retrospectively. Patients with suspected malignant findings underwent fine-needle or core biopsy followed by surgery and histopathological examination of the specimens. Patients without suspected malignant findings were followed for at least 12 months to establish the absence of cancer. If patients had a previous mastectomy, breast implants (including in the opposite breast), or previous breast cancer treatment, they were further excluded from analysis because of the effects these procedures can have on breast architecture. Men were also excluded. Ultimately, 1164 breasts (628 patients; age range: 22–91 years; mean age: 50.2 years) were evaluated.

Image acquisition

Both CDM and DBT images were obtained using a commercially available system (Senographe Essential; GE Healthcare Japan, Tokyo, Japan). The detector used in this system was an amorphous silicon flat-panel detector. The CDM and DBT images were acquired using a tube anode/filter combination (Mo/Mo, Mo/Rh, Rh/Rh) as determined by the automatic exposure control of the unit. Nine projections images were obtained with a total tomosynthesis angle of 25°, acquired in step-and-shoot mode while the breast was compressed in the fixed position. Using this machine, the mean radiation dose for DBT in both breasts in a single view was approximately 1.47 mGy. All patients concurrently underwent DBT in one view (medial lateral oblique) and CDM in two views (craniocaudal and medial lateral oblique). DBT examination was performed immediately after CDM by the

same designated technician. CDM and DBT images were obtained in the same compression mode using automatic exposure control.

Image review

DBT images were reconstructed using the successive approximation method and divided into thin 0.5-mm slices and thick 10-mm slabs for viewing on a workstation. Three radiologists, who read at least 1,000 CDM studies and 300 DBT studies per year combined, interpreted both the CDM and DBT images on 8 MG monitors. Each radiologist first evaluated the CDM image while blinded to the DBT image and the patient's clinical information, and assigned a Breast Imaging Reporting and Database System (BI-RADS) category [17]. The radiologist then evaluated the DBT image and assigned a BI-RADS category to that as well. When the assigned BI-RADS categories differed among the radiologists, a consensus was reached through discussion.

BI-RADS categories 1, 2, and 3 were identified as negative, while categories 4 and 5 were identified as positive. The pathological findings from surgery and biopsy were used as the gold standard for the diagnosis of breast cancer. Lesions such as fibroadenoma and breast cysts that did not appear to change on ultrasonography during an observation period of at least 12 months were identified as benign lesions.

Statistical analysis

The overall comparison of clinical performance was derived from the differences between the mean areas under the receiver operating characteristic (ROC) curves. Fisher's exact test was used to compare the sensitivity, specificity, positive predictive value, and negative predictive value. A p-value < 0.05 was considered statistically significant.

Results

In this study, of the 1164 breasts analyzed, 100 breasts were found to have cancer. Biopsy was performed in 226 of 1164 cases. Of the cancers, 74 were invasive ductal carcinomas, 19 were ductal carcinomas in situ, 4 were invasive lobular carcinomas, 1 was a mucinous carcinoma, and 1 was an apocrine carcinoma. Histological diagnosis was unknown in 1 case because the patient was diagnosed with breast cancer via biopsy but switched hospitals afterwards; therefore, her postoperative histological results were not available. Comparison of categories of all breasts and all carcinoma cases is presented in Table 1. The percentage of dense breasts (i.e., extremely dense or heterogeneously dense) was 85.1% (990/1164), and that of scattered or fatty breasts was 14.9% (174/1164).

ROC curves of CDM alone and CDM plus DBT

The areas under the ROC curves were 0.916 (95% confidence interval, 0.878–0.954) for CDM alone and 0.938 (95% confidence interval, 0.902–0.973) for CDM plus DBT. Using BI-RADS category 4 as a cut-off for diagnosing breast cancer in both CDM alone and CDM plus DBT, breast tumors were diagnosed with sensitivities of 61.0% (61/100) and 83.0% (83/100), specificities of 99.1% (1054/1064) and 98.9% (1052/1064), positive predictive values of 85.9% (61/71) and 87.4% (83/95), and negative predictive values of 96.4% (1054/1093) and 98.4% (1052/1069), respectively (Figure 1). Sensitivity was significantly higher in CDM plus DBT than in CDM alone (p = 0.0009). No significant differences were observed in the specificity, positive predictive value, or negative predictive value between CDM plus DBT and CDM alone. There were no adverse events.

Improvement in diagnostic performance by adding DBT

CDM alone yielded 39 false-negative diagnoses. With the inclusion of DBT, breast cancer was diagnosed in 56.4% of these cases (22/39). Of the 22 lesions, 15 were invasive ductal carcinomas, 5 were ductal carcinoma in situ lesions, 1 was invasive lobular lesion, and

1 was mucinous carcinoma. The descriptions of the findings are shown in Table 2 and Figures 2–4. Regarding breast density, 86.4% (19/22) of the breasts were dense and 13.6% (3/22) were scattered or fatty.

False-negative cases by CDM plus DBT

CDM plus DBT failed to diagnose cancer in 17 cases, of which 7 were invasive ductal carcinomas, 9 were ductal carcinomas in situ, and 1 was an invasive lobular carcinoma. Regarding breast density, 82.4% (14/17) of the breasts were dense and 17.6% (3/17) were scattered or fatty. The pathological types of carcinoma are listed in Table 3. Eight cases were miscategorized as BI-RADS category 3 by both CDM alone and CDM plus DBT: 7 as calcifications and 1 as a mass. These lesions were suspected of being malignant by ultrasonography after CDM, follow-up CDM, or ultrasonography, and were subsequently verified as such.

False-positive cases

CDM plus DBT yielded false-positive diagnoses in 12 cases. In 2 of these cases, the CDM findings were considered negative, although the DBT images showed indistinct masses and were considered positive. Ultimately, these lesions were deemed to be benign on follow-up ultrasonography or fine-needle aspiration. As for the other 10 cases that were diagnosed as false-positive on both CDM alone and CDM plus DBT, calcification observed in 9 cases was diagnosed as mastopathy or benign lesions upon follow-up ultrasonography or biopsy. One case with an indistinct mass was proven to be a benign phyllodes tumor following surgery.

Discussion

This study demonstrated an improvement in breast cancer diagnostic performance with the combined use of CDM and DBT. When CDM and DBT were combined, the false-negative rate decreased and sensitivity increased as compared to using only CDM (61.0% to 83.0%). However, the area under the ROC curve for CDM alone was already high (0.916), and was therefore not significantly different from that for CDM plus DBT (0.938). DBT is particularly useful for detecting breast cancer with mass formation because DBT shows the tumor contour more precisely and increases the tumor's contrast in comparison to normal mammary tissue [18]. Since DBT provides a definite depiction of a lesion, the method should be able to distinguish between benign and malignant lesions. In the current study, DBT contributed to the discovery of 22 carcinomas, suggesting DBT is a helpful tool for discriminating between tumors and normal mammary gland tissue in dense breasts [19]. Consequently, we expect that adding DBT is beneficial for Japanese women who have dense breasts or a symptom of breast mass. Furthermore, including DBT facilitates the detection of focal asymmetries and lesions with architectural distortions, which are often observed in breast cancer.

The ability of DBT to assess calcification has not been established [20–22]. In the current study, DBT was not inferior to CDM for the detection of calcified lesions. In addition, DBT exhibited a clearer spatial distribution of calcifications in the mammary ducts as compared to CDM (Figure 4). Therefore, this study showed that DBT might also be useful for the assessment of calcifications in some cases. These advantages contribute to a reduction in unnecessary biopsies and subsequently alleviate patients' mental and economic burdens. Further, these advantages improve the confidence of the radiologist's diagnosis. Previous studies have indicated that DBT reduces the number of category 3 cases, which comprise the majority of cases with focal asymmetries [22]. In contrast, in the present study, adding DBT

increased the number of cases with category 3 (Table 1), including 58 mass lesions with a clear margin, suggesting benign lesions. Finally, these were diagnosed as cysts (38), fibroadenomas or mastopathies (18), and intraductal papillomas (2) by ultrasonography and biopsy. This is considered a reason for the increase of category 3 cases.

This study had several limitations. First, since our hospital is not a screening facility, but a facility that conducts scrutiny and treatment, most patients that were included in this study presented with some symptoms or abnormalities in screening mammography. Further, only the patients who underwent mammography for the first time at our hospital were selected. Thus, some degree of selection bias could not be avoided. Finally, the number of patients was relative small in comparison to other screening studies [23, 24].

Conclusion

This study demonstrated that the combination of DBT and CDM for the diagnosis of breast cancer in women with abnormal screening findings or clinical symptoms proved effective and should be used to improve the diagnostic performance of breast cancer examination and investigate patients with abnormal findings or those who present with clinical symptoms.

Acknowledgments

Conflicts of interest: None

References

1. Smith RA, Duffy SW, Tabár L. Breast cancer screening: the evolving evidence. Oncology 2012;26:471–86.
2. Shapiro S, Venet W, Strax P, Venet L, Roeser R. Ten- to fourteen-year effect of screening on breast cancer mortality. J Natl Cancer Inst 1982;69:349–55.
3. Tabár L, Fagerberg CJ, Gad A, Baldetorp L, Holmberg LH, Gröntoft O, et al. Reduction in mortality from breast cancer after mass screening with mammography. Randomised trial from the Breast Cancer Screening Working Group of the Swedish National Board of Health and Welfare. Lancet 1985;1:829–32.
4. Andersson I, Aspegren K, Janzon L, Landberg T, Lindholm K, Linell F, et al. Mammographic screening and mortality from breast cancer: the Malmö mammographic screening trial. BMJ 1988:297:943–8.
5. Nyström L, Andersson I, Bjurstam N, Frisell J, Nordenskjöld B, Rutqvist LE. Long–term effects of mammography screening: updated overview of the Swedish randomised trials. Lancet 2002;359:909–19.
6. Alexander FE, Anderson TJ, Brown HK, Forrest AP, Hepburn W, Kirkpatrick AE, et al. 14 years of follow–up from the Edinburgh randomised trial of breast–cancer screening. Lancet 1999;353:1903–8.
7. Tabár L, Vitak B, Chen TH, Yen AM, Cohen A, Tot T, et al. Swedish two-county trial: impact of mammographic screening on breast cancer mortality during 3 decades. Radiology 2011;260:658–63.
8. Carney PA, Miglioretti DL, Yankaskas B, Kerlikowske K, Rosenberg R, Rutter CM, et al. Individual and combined effects of age, breast density, and hormone replacement therapy use on the accuracy of screening mammography. Ann Intern Med 2003;138:168–75.

9. Leconte I, Feger C, Galant C, Berlière M, Berg BV, D'Hoore W, et al. Mammography and subsequent whole-breast sonography of nonpalpable breast cancers: the importance of radiologic breast density. AJR Am J Roentgenol 2003;180:1675–9.

10. del Carmen MG, Halpern EF, Kopans DB, Moy B, Moore RH, Goss PE, et al. Mammographic breast density and race. AJR Am J Roentgenol 2007;188:1147–50.

11. Tice JA, Cummings SR, Smith-Bindman R, Ichikawa L, Barlow WE, Kerlikowske K. Using clinical factors and mammographic breast density to estimate breast cancer risk: development and validation of a new predictive model. Ann Intern Med 2008;148:337–47.

12. Sechopoulos I. A review of breast tomosynthesis. Part I. The image acquisition process. Med Phys 2013;40:014301.

13. Greenberg JS, Javitt MC, Katzen J, Michael S, Holland AE. Clinical performance metrics of 3D digital breast tomosynthesis compared with 2D digital mammography for breast cancer screening in community practice. AJR Am J Roentgenol 2014;2013:687–93.

14. Friedewald SM, Rafferty EA, Rose SL, Durand MA, Plecha DM, Greenberg JS, et al. Breast cancer screening using tomosynthesis in combination with digital mammography. JAMA 2014;311:2499–507.

15. Skaane P, Bandos AI, Gullien R, Eben EB, Ekseth U, Haakenaasen U, et al. Comparison of digital mammography alone and digital mammography plus tomosynthesis in a population-based screening program. Radiology 2013;267:47–56.

16. Ciatto S, Houssami N, Bernardi D, Caumo F, Pellegrini M, Brunelli S, et al. Integration of 3D digital mammography with tomosynthesis for population breast cancer screening (STORM): a prospective comparison study. Lancet Oncol 2013;14:583–9.

17. Breast imaging reporting and data system (BI-RADS) atlas. 5th ed. Reston, VA: American College Of Radiology; 2013.

18. Takamoto Y, Tsunoda H, Kikuchi M, Hayashi N, Honda S, Koyama T, et al. Role of breast tomosynthesis in diagnosis of breast cancer for Japanese women. Asian Pac J Cancer Prev 2013;14:3037–40.

19. Mun HS, Kim HH, Shin HJ, Cha JH, Ruppel PL, Oh HY, et al. Assessment of extent of breast cancer: comparison between digital breast tomosynthesis and full-field digital mammography. Clin Radiol 2013;68:1254–9.

20. Poplack SP, Tosteson TD, Kogel CA, Nagy HM. Digital breast tomosynthesis: initial experience in 98 women with abnormal digital screening mammography. AJR Am J Roentgenol 2007;189:616-23.

21. Spangler ML, Zuley ML, Sumkin JH, Abrams G, Ganott MA, Hakim C, et al. Detection and classification of calcifications on digital breast tomosynthesis and 2D digital mammography: a comparison. AJR Am J Roentgenol 2011;196:320–4.

22. Raghu M, Durand MA, Andrejeva L, Goehler A, Michalski MH, Geisel JL, et al. Tomosynthesis in the diagnostic setting: changing rates of BI-RADS final assessment over time. Radiology 2016:281:54-61.

23. Giess CS, Pourjabbar S, Ip IK, Lacson R, Alper E, Khorasani R. Comparing Diagnostic Performance of Digital Breast Tomosynthesis and Full-Field Digital Mammography in a Hybrid Screening Environment. AJR Am J Roentgenol 2017;209:929-34..

24. Powell JL, Hawley JR, Lipari AM, Yildiz VO, Erdal BS, Carkaci S. Impact of the Addition of Digital Breast Tomosynthesis (DBT) to Standard 2D Digital Screening Mammography on the Rates of Patient Recall, Cancer Detection, and Recommendations for Short-term Follow-up. Acad Radiol 2017;24:302-7.

Figure Legends

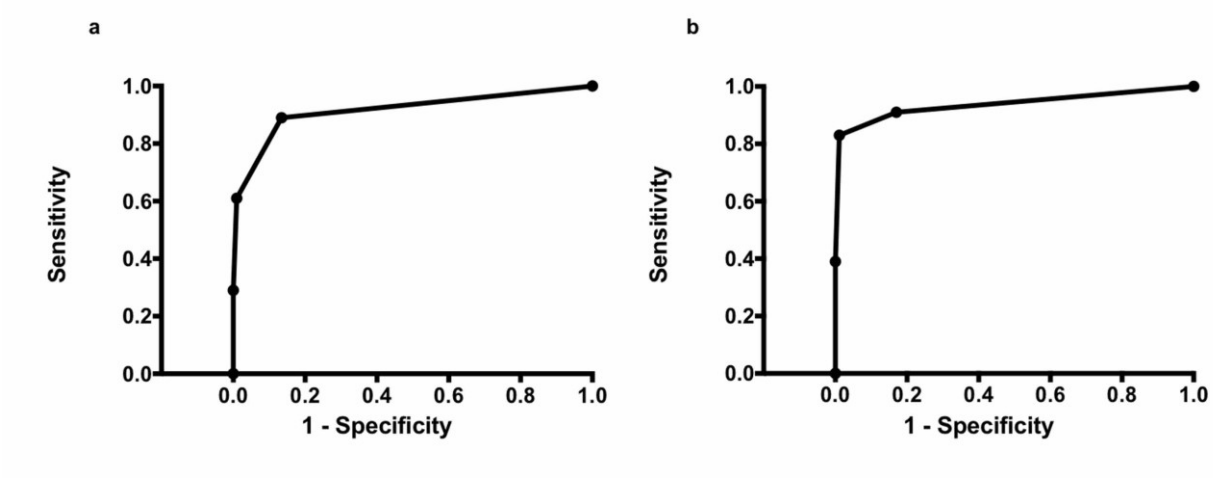

Figure 1

Receiver operating characteristics curves for (a) conventional digital mammography alone and (b) conventional digital mammography plus digital breast tomosynthesis.

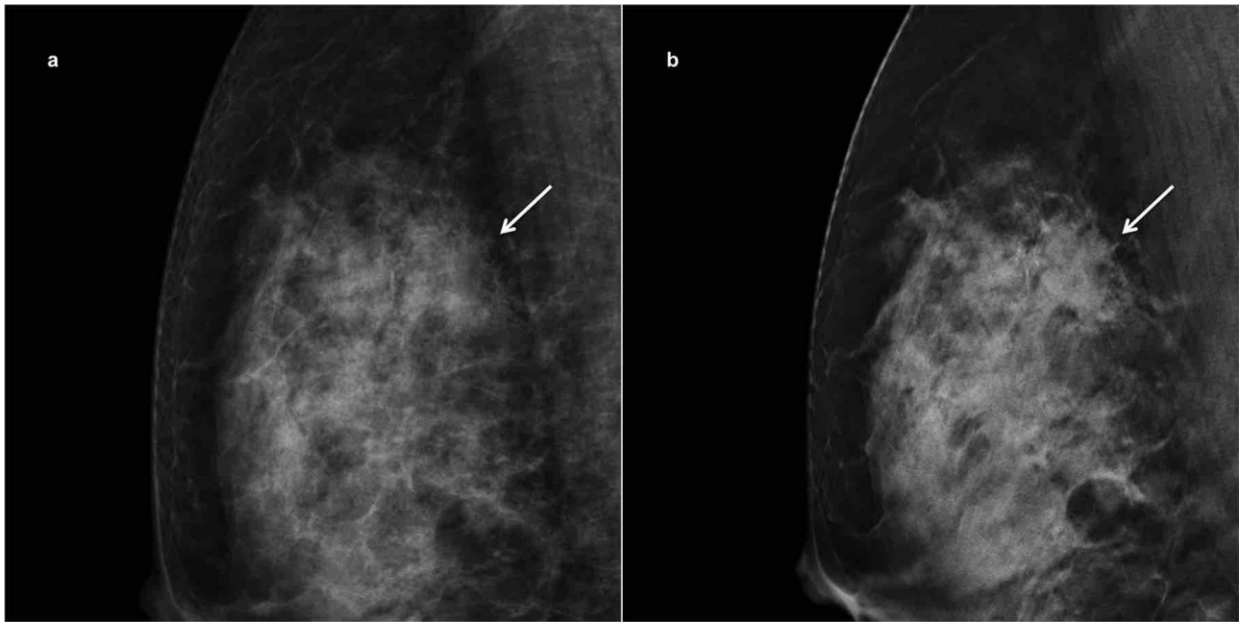

Figure 2

A 37-year-old woman with invasive ductal carcinoma. (a) A CDM image shows focal asymmetries in the upper portion of the right breast in the MLO view; and (b) a DBT image shows an irregular mass with a spiculated margin in the corresponding area of right breast. CDM, conventional digital mammography; DBT, digital breast tomosynthesis; MLO, mediolateral oblique

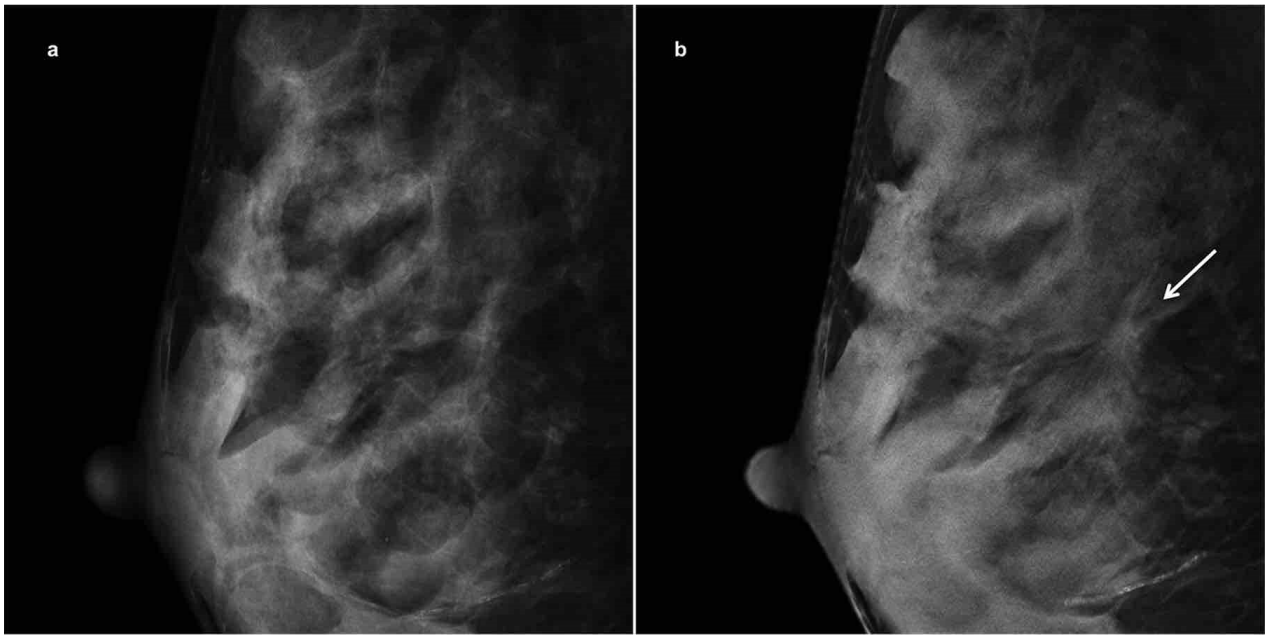

Figure 3

A 54-year-old woman with invasive ductal carcinoma. (a) No lesion is detected on the CDM image. (b) DBT shows irregular mass with architectural distortion in the middle portion of the right breast in the MLO view.

CDM, conventional digital mammography; DBT, digital breast tomosynthesis; MLO, mediolateral oblique

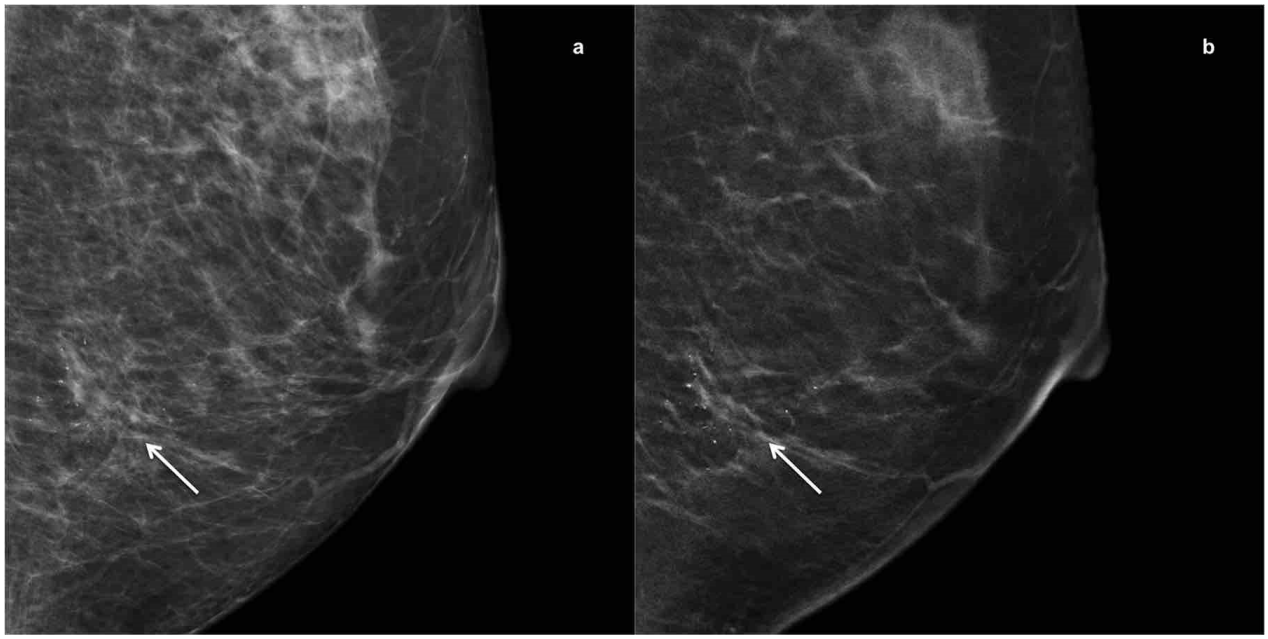

Figure 4

A 68-year-old woman with ductal carcinoma in situ. (a) A CDM image shows grouped microcalcifications in the lower portion of the left breast in the MLO view. (b) A DBT image shows microcalcifications arrayed in a line.

CDM, conventional digital mammography; DBT, digital breast tomosynthesis; MLO, mediolateral oblique

Tables

Table 1. Comparison of BI-RADS categories using CDM alone vs. CDM plus DBT for all cases (a) and all carcinoma cases (b)

(a) all cases

CDM alone category	CDM plus DBT category: 1 or 2	3	4	5	**Total**
1 or 2	869	61	1	1	932
3	23	116	22	0	161
4	0	0	33	9	42
5	0	0	0	29	29
Total	892	177	56	39	1164

(b) all carcinoma cases

CDM alone	CDM plus DBT: 1 or 2	3	4	5	**Total**
1 or 2	9	0	1	1	11
3	0	8	20	0	28
4	0	0	23	9	32
5	0	0	0	29	29
Total	9	8	44	39	100

BI-RADS, Breast Imaging Reporting and Database System; CDM, conventional digital mammography; DBT, digital breast tomosynthesis

Table 2. Improvement in diagnostic performance by including DBT

BI-RADS, Breast Imaging Reporting and Database System; CDM, conventional digital

CDM alone BI-RADS Category 1,2,3	CDM+DBT BI-RADS Category 4,5	Number	Pathological type	Number
Mass				
Focal asymmetries	Irregular mass	8	IDC DCIS ILC MC	4 2 1 1
Mass (suspected as benign)	Mass (suspicion for malignancy)	4	IDC	4
Calcification (suspected as benign)	Calcifications + irregular mass	1	IDC	1
Occult	Irregular mass with distortion	1	IDC	1
Architectural distortion				
Focal asymmetries	Architectural distortion	2	IDC	2
Suspect architectural distortion	Architectural distortion	1	IDC	1
Occult	Architectural distortion	1	DCIS	1
Calcifications				
Calcifications (suspected as benign)	Calcifications (suspicion for malignancy)	3	IDC DCIS	1 2
Focal asymmetries	Focal asymmetries + calcifications	1	IDC	1

mammography; DBT, digital breast tomosynthesis; IDC, invasive ductal carcinoma; DCIS, ductal carcinoma in situ; ILC, invasive lobular carcinoma; MC, mucinous carcinoma.

Table 3. Pathological type of false negative cases by CDM+DBT (n = 17)

CDM alone BI-RADS Category	CDM+DBT BI-RADS Category	Pathological type	Number
1 or 2	1 or 2	IDC	3
		DCIS	5
		ILC	1
3	3	IDC	4
		DCIS	4

BI-RADS, Breast Imaging Reporting and Database System; CDM, conventional digital mammography; DBT, digital breast tomosynthesis; IDC, invasive ductal carcinoma; DCIS, ductal carcinoma in situ; ILC, invasive lobular carcinoma.