J Tokyo Wom Med Univ
81 (3) 185~188 (2011)

Report

A Case of Emphysematous Cystitis Associated With Septic Shock and Disseminated Intravascular Coagulopathy

Masayoshi NISHINA, Hiroyasu SUGA, Yoshizumi DEGUCHI, Toshimitsu YOKOYAMA, Takayuki SATO, Shunshi NISHIKUBO, Takamitsu MASUDA and **Takao NAKAGAWA**

Emergency and Critical Care Center, Tokyo Women's Medical University Medical Center East

(Accepted May 24, 2011)

Emphysematous cystitis is a rare but critical radiographic finding. A 74-year-old man with septic shock, urinary retention, macrohematuria and pneumaturia was transferred from another hospital to our emergency and critical care center. A plain abdominal X-ray revealed radiolucent band centered in the pelvis. Enhanced abdominal computed tomography revealed gas in the intramural region and in the lumen. Urine cultures confirmed *Klebsiella sp.* He was treated in our intensive care unit with a broad-spectrum antibiotic, gabexate mesilate, dobutamine, noradrenalin, gamma-globulin and an insulin infusion. On the following day, septic shock continued and the platelet count had decreased. We added endotoxin absorption therapy, which rapidly improved his condition. Clinicians should be aware that emphysematous cystitis might proceed to septic shock and disseminated intravascular coagulopathy.

Key Words: emphysematous cystitis, septic shock, disseminated intravascular coagulopathy

Introduction

Emphysematous cystitis is a rare but critical radiographic finding[1)~6)] that is frequently associated with severe infection. We describe a patient with emphysematous cystitis associated with septic shock and disseminated intravascular coagulopathy.

Case

A 74-year-old man without a remarkable medical history was transferred from another hospital to our emergency and critical care center due to septic shock. Ten days previously, he had been admitted to that hospital with heat exhaustion. Eight days thereafter, his condition improved. At the day, his blood urea nitrogen (BUN) was 17.0 mg/dl and creatinine was 0.93 mg/dl, either were normal. However, on the day before admission to our institution, he developed urinary retention, macrohematuria and pneumaturia. Catheter insertion relieved about 800 ml of urine. Fever was 39.5℃.

He was sick and somnolent upon arrival. His vital signs were as follows: systolic blood pressure, 90 mmHg; heart rate, 92 beats/min; respiratory rate, 20 breaths/min. His conjunctivae were not anemic and an abdominal examination revealed no tenderness or muscle guarding.

Laboratory data revealed the following: hemoglobin 11.5 g/dl, white blood cells 14,600 /μl; platelets, 4.7×10^4 /μl; C-reactive protein, 11.17 mg/dl; BUN, 39.0 mg/dl; creatinine, 1.82 mg/dl; and HbA_{1c}, 6.7%. The urine was wine red (macrohematuria). Arterial blood gas analysis showed a base excess of −24.4 mmol/*l*, indicating severe metabolic acidosis. Ultrasound of the bladder showed air in the wall. Urine cultures revealed *Klebsiella sp.* and we indicated the drug sensitivity of the detected *Klebsiella sp.* (Table). Cytology revealed no malignant cells.

A plain abdominal X-ray showed radiolucent band centered in the pelvis (Fig. 1) and enhanced abdominal computed tomography (CT) revealed gas in the intramural region and in the bladder lumen (Fig. 2). Benign prostate hypertrophy was not evident. We did not perform a cystoscopic examination to avoid the possibility of damaging the bladder

Table The drug sensitivity of the detected *Klebsiella sp.*

Amoxicillin	R
Cefazolin	S
Cefaclor	S
Cefotiam	S
Ceftriaxone	S
Cefdinir	S
Cefditoren	S
Cefpirome	S
Cefozopran	S
Cefcapene	S
Meropenem	S
Faropenem	S
Levofloxacin	S
Minocycline	S
Dibekacin	S
Fosfomycin	S

R: resistant, S: sensitive.

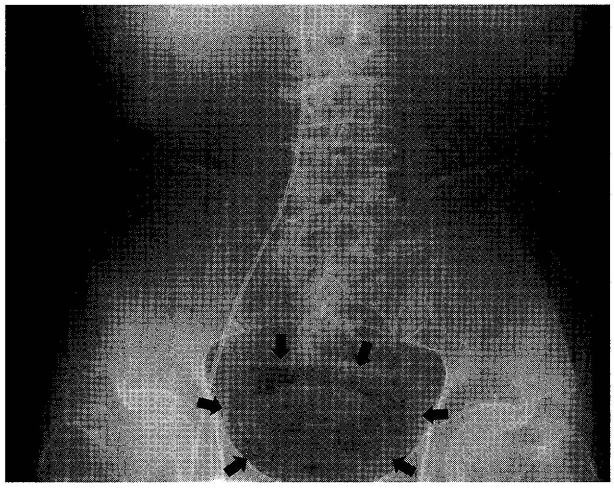

Fig. 1 The plain abdominal X-ray findings on arrival
The plain abdominal X-ray showed radiolucent band centered in the pelvis (black arrows).

wall.

We treated the patient in our intensive care unit, because of the septic shock and disseminated intravascular coagulopathy (under the criteria of acute phase disseminated intravascular coagulopathy: thrombocytopenia and SIRS: systemic inflammatory responce syndrome[7]). He was treated with an antibiotic (meropenem), gabexate mesilate[8], dobutamine, noradrenalin, gamma-globulin[9] and an insulin infusion. The septic shock state continued on the next day, and the platelet count decreased to 2.1×10^4 /μl. The blood pressure fell down to 60

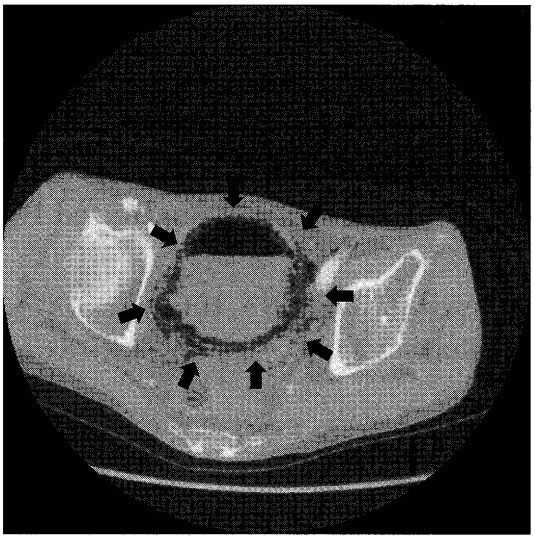

Fig. 2 The enhanced abdominal CT findings on arrival
The enhanced abdominal computed tomography revealed gas in the intramural (black arrows) and in the lumen (horizontal line).

mmHg even with dobutamine and noradrenalin. We performed endotoxin absorption therapy[10)11)], using Toraymixin PMX-20R (Toray Medical CO LTD. Chiba, Japan), flow volume 100 ml/min, 2 hours. After endotoxin absorption therapy rapidly improved the blood pressure. We thus stopped the dobutamine and noradrenalin, administration. On day 13, CT findings showed that the intramural gas had diminished. The platelet count, BUN and creatinine reached 25.8×10^4 /μl, 8.8 mg/dl and 0.68 mg/dl, respectively, which were all normal. On day 14, he was transferred back to the original hospital to continue rehabilitation.

Discussion

Emphysematous cystitis is a rare but a potentially life-threatening condition[1)2)] that is characterized by gas collection inside the bladder wall[1)~6)] caused by bacteria or fungus[1)2)]. Clinical symptoms and signs are irritable bladder, pyuria, hematuria and pneumaturia[1)2)].

Emphysematous cystitis is mainly diagnosed radiographically[1)2)]. A plain X-ray is the most common imaging modality and that of the abdomen shows a curvilinear or mottled "beaded necklace" appearance of the bladder[6)]. Abdominal CT is more accurate because it can show gas in the bladder wall

with or without intramural involvement[1)~5)] and differentiate other important findings, such as vesicocolic fistula, neoplasm or an abcess[1)2)].

Thomas et al[1)] reviewed 135 patients (female, 64%; median age, 66 years) with emphysematous cystitis in 2007. The overall mortality was 7% and 67% was associated with diabetes mellitus[1)]. Urine cultures revealed *Escherichia coli* in 58%. Followed by *Klebsiella* in 21%[1)] of their patients. We should take a blood culture. We reflect this point. We suspected the septic shock of the patient was due to the complex infection from emphysematous cystitis. Recently, many strains of *E.coli* and *Klebsiella* had β-lactamase, so we administered meropenem.

Our patient did not apparently have diabetes, although the HbA_{1c} was high. A CT scan revealed the absence of benign prostate hypertrophy.

Treatment for emphysematous cystitis consisting of antibiotics, bladder drainage, and blood sugar control is generally successful and surgical intervention is relatively infrequent[1)2)]. Intensive care including endotoxin absorption therapy[12)] was useful for this patient who developed septic shock and disseminated intravascular coagulopathy.

The efficacy of gamma-globulin for septic shock is still controversial. Turgeon et al[9)] reported the efficacy of gamma-globulin by analysis of randomized controlled trials, however the dosage of administered gamma-globulin was 1 g/kg of body weight. This was very large volume comparing to the commonly using in Japan.

Cruz et al[10)] reported the systemic review of the endotoxin absorption therapy for septic shock. The gram negative infections were identified in 71% of patients. They found positive effects on mean arterial pressure, vasoactive drugs, endotoxin removal, and motality.

Conclusion

Clinicians should consider that emphysematous cystitis might progress to septic shock and disseminated intravascular coagulopathy.

References

1) **Thomas AA, Lane BR, Thomas AZ et al**: Emphysematous cystitis: a review of 135 cases. BJU Int **100**: 17–20, 2007
2) **Grupper M, Kravtsov A, Potasman I**: Emphysematous cystitis: illustrative case report and review of the literature. Medicine **86**: 47–53, 2007
3) **Lakhal K, Paubelle E**: Emphysematous cystitis. Lancet **372**: 1184, 2008
4) **Asada S, Kawasaki T**: Emphysematous cystitis. N Engl J Med **349**: 258, 2003
5) **Reese AC, Stoller ML**: Emphysematous cystitis. Urology **75**: 1315–1316, 2010
6) **Grayson DE, Abbott RM, Levy AD et al**: Emphysematous infections of the abdomen and pelvis: a pictorial review. Radiographics **22**: 543–561, 2002
7) **Gando S, Iba T, Eguchi Y et al**: A multicenter, prospective validation of disseminated intravascular coagulation diagnostic criteria for critically ill patients: Comparing current criteria. Crit Care Med **34**: 625–631, 2006
8) **Maruyama I, Sakata Y, Wada H et al**: Expert consensus based on the evidence for the treatment of disseminated intravascular coagulation due to infection intravascular. Jpn J Thromb Hemost **20**: 77–113, 2009 (in Japanese)
9) **Turgon AF, Hutton B, Fergusson DA et al**: Meta-analysis: intravenous immunoglobulin in critically ill adult patients with sepsis. Ann Intern Med **35**: 2693–2701, 2007
10) **Cruz DN, Perazella MK, Bellomo R et al**: Effectiveness of polymyxin B-immobilized fiber column in sepsis: a systematic review. Crit Care **11**: R47, 2007
11) **Cruz DN, Antonelli M, Fumagalli R et al**: Early use of polymyxin B hemoperfusion in abdominal septic shock. The EUPHAS randomized controlled trial. JAMA **301**: 2445–2452, 2009
12) **Komeya M, Matsumoto T, Fujinami K et al**: A case of urosepsis due to the left uretheral stone for which endotoxin adsorption therapy was effective. Jpn J Urol Surg **23**: 1633–1636, 2010 (in Japanese with English abstract)

敗血症性ショックと播種性血管内凝固症候群を合併した気腫性膀胱炎の１例

東京女子医科大学東医療センター救急医療科
仁科（ニシナ） 雅良（マサヨシ）・須賀（スガ） 弘泰（ヒロヤス）・出口（デグチ） 善純（ヨシズミ）・横山（ヨコヤマ） 利光（トシミツ）
佐藤（サトウ） 孝幸（タカユキ）・西久保俊士（ニシクボシュンシ）・増田（マスダ） 崇光（タカミツ）・中川（ナカガワ） 隆雄（タカオ）

気腫性膀胱炎は特徴的な画像所見を呈するまれな疾患である．今回我々は敗血症性ショックと播種性血管内凝固症候群を合併した気腫性膀胱炎の１例を経験したので報告する．症例は74歳の男性．他院から敗血症性ショックのため搬送された．尿閉・血尿・気尿がみられた．腹部単純レントゲン撮影では骨盤部に透亮像があり，腹部造影CT撮影では膀胱内および膀胱壁に気体像がみられた．尿培養では *Klebsiella* が検出された．抗菌薬・メシル酸ガベキサート・ドブタミン・ノルアドレナリン・グロブリン製剤などを使用して集中治療室で治療した．しかし，翌日状態が改善しないためエンドトキシン吸着療法を行ったところ状態が急速に改善した．気腫性膀胱炎では敗血症性ショックや播種性血管内凝固症候群を合併することを念頭におくべきである．